

Snake Fungal Disease (SFD) in Wisconsin

What is this disease?

Severe skin infections appear to be an emerging disease in certain populations of wild snakes in the eastern half of the U.S. The disease was first reported in New England and Illinois in 2006 and 2008, respectively. However, clinical signs that may represent the same disease have been described from the eastern U.S. (including Wisconsin and Minnesota) for the last few decades. Many types of snakes are impacted; however the disease seems to be more frequently reported in certain species (rattlesnakes [*Crotalus* spp.], rat snakes [*Pantherophis* spp.], racers [*Coluber* spp.], and milksnakes [*Lampropeltis triangulum*]). The USGS - National Wildlife Health Center (NWHC) has confirmed cases of SFD (or the fungus that causes the disease) in snakes from Alabama, Connecticut, Illinois, Florida, Kentucky, Louisiana, Massachusetts, Minnesota, New Jersey, New Hampshire, New York, Ohio, South Carolina, Tennessee, Vermont, Virginia, and Wisconsin; however the disease is likely more widespread than is currently documented.

What causes this disease?

The causative agent of SFD is the fungus *Ophidiomyces ophiodiicola*. However, the mere presence of *O. ophiodiicola* does not necessarily mean that a snake has SFD as the fungus is occasionally found on the skin of healthy snakes.

How do I know if a snake has this disease?

Infections related to this disease can manifest in multiple ways. The most common symptoms include crusty scabs on the surface of the skin, thickening of the skin (often yellowish in coloration), and/or the presence of lumps (nodules) beneath the skin. Eye infections, blisters, premature sloughing of the skin (outside of a typical molt), and swelling associated with the lesions may also be present. In some snakes (especially the pit vipers), the face is most impacted and may become disfigured as a result of swelling and granuloma formation. In other species or individuals, skin blisters and/or crusty scales or sores on the back, sides, and/or belly may be the only sign of disease. The type of clinical sign is often related to the stage of infection. Early on in the infection, affected scales are often swollen and filled with fluid (like a blister), but eventually become hard and crusty. Immediately after infected snakes shed their skin, lesions may be less noticeable (at least temporarily). Old lesions are usually visible on the sheds as orange- to brown-colored thickened areas of skin. Pictures that demonstrate the types of lesions that occur as a result of this disease can be found at the end of this document. While the pictures serve as helpful guides in assessing whether a snake may have SFD, laboratory testing is necessary to confirm the diagnosis.

Which species of snakes develop the disease?

Several species of snakes have been diagnosed with SFD, and nearly all species living in Wisconsin are believed to be susceptible to the disease. In Wisconsin, the fungus that causes SFD has been found on timber rattlesnakes (*Crotalus horridus*), milksnakes, and western foxsnakes (*Pantherophis vulpinus*) with clinical signs of the disease. Many other snake species in Wisconsin have been observed with infections consistent with SFD, but no laboratory testing was done to confirm the diagnosis.

Is this disease a threat to Wisconsin snakes?

In parts of Illinois and the Northeastern U.S., certain rattlesnake populations are undergoing declines for which SFD appears to be a contributing factor. In these populations, disease prevalence is high and the infections become very severe. In other areas where SFD has been documented, there is no evidence that snake populations are declining. For example, symptoms consistent with SFD have been observed for years in Wisconsin without obvious detriment to some of the species it infects (such as milksnakes). For species that are already in decline due to a multitude of other threats (e.g. timber rattlesnake, eastern massasauga [*Sistrurus catenatus*], North American racer [*Coluber constrictor*], and gophersnake [*Pituophis catenifer*]), it is unclear whether SFD poses a significant risk. The secretive nature of snakes makes monitoring the effects of SFD difficult. Also complicating elucidation of disease impact is that there are clear variations in disease severity between different geographic regions which may be linked to strain differences in the pathogen, genetic composition of a given snake population, or environmental and/or behavioral factors that influence disease ecology. The USGS - National Wildlife Health Centers (NWHC), along with the Wisconsin Department of Natural Resources (DNR) is currently investigating SFD in Wisconsin to better understand the risks posed to our native snakes.

Examples of SFD

Confirmed Cases of SFD



Racer with cloudy eyes, scabs on the chin and snout, and thickened scales on the neck. Photograph by D.E. Green, USGS National Wildlife Health Center.



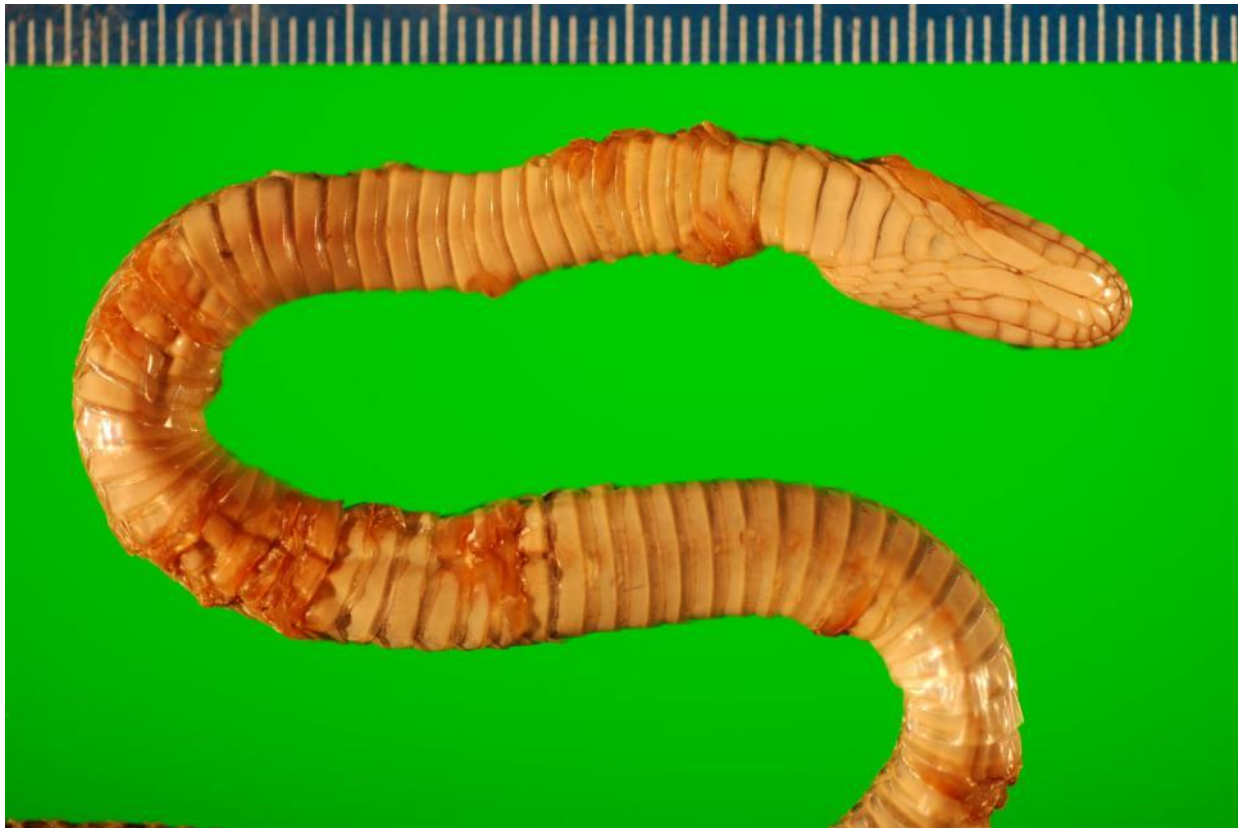Milksnake with crusty skin on the snout and a severe mouth infection. The snout is a common site of infection in many snakes. This particular animal also had several nodules below the skin on the back half of the body (not shown). Photograph by D.E. Green, USGS National Wildlife Health Center.



Belly scales of an infected racer. The white spots indicate thickening skin. A single brown spot (scab) is also visible. Photograph by D.E. Green, USGS National Wildlife Health Center.



Tail of an infected pygmy rattlesnake. Note the numerous lumps (nodules) below the skin which are caused by the fungus. Photograph by D.E. Green, USGS National Wildlife Health Center.



Water snake with numerous scabs, nodules, and blisters. This is a severe case and the animal died as a result of the infection. Photograph by D.E. Green, USGS National Wildlife Health Center.



Ratsnake demonstrating scabbing and thickening of the skin on the snout, chin, jaw, and eye. Photograph by D.E. Green, USGS National Wildlife Health Center.




Patch of thickened, crusty scales on the side of the body of the same ratsnake. Photograph by D.E. Green, USGS National Wildlife Health Center.

Suspected Cases of SFD in Wisconsin Snakes



Milk snake with a nodule below the skin (arrow) and thickened/scabby scales (circled).
Photograph by Jeff Lorch, USGS National Wildlife Health Center.




Milk snake with two areas of thickened scales. Photograph by Jeff Lorch, USGS National Wildlife Health Center.



Milk snake found dead in the field with numerous nodules (arrows) and thickened scales (arrowhead) on the body. Also note the mixture of shiny and dull scales. Photograph by Jeff Lorch, USGS National Wildlife Health Center.



Milksnake with several areas of thickened skin. Photograph by Jeff Lorch, USGS National Wildlife Health Center.



Racer (upper left) and milksnake (upper right and bottom) with thickened skin on the snout and chin (circled). Thickened, yellow skin is also visible on the neck in the bottom picture (arrow). The milksnake in these pictures was in the process of shedding. Photograph by Jeff Lorch, USGS National Wildlife Health Center.



Milksnake with area of thickened, dead skin on the ventral scales. Photograph by Jeff Lorch, USGS National Wildlife Health Center.